

Literature Review of Treatment of Challenging Macular Holes

Zeyad Abdel Fadeel Hussein¹, Hossam Al Din Mohamed Moharram¹, Ahmed Mohamed Sabry¹, Mohamed Farouk Sayed Othman¹, Mohamed Abdel Hamid¹

Department of Ophthalmology, Faculty of Medicine, Minia University, Minia, Egypt¹



Keywords:

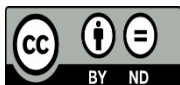
Macular holes, ILM flap techniques, autologous retinal transplantation, amniotic membrane grafts, plasma-rich growth factors, CLOSE classification, refractory macular holes cases, adjuvant therapies.

DOI:

01.1233/Fyxzz.29.01.2025.01

ABSTRACT

Full-thickness macular holes (FTMHs), particularly challenging cases such as large (>650 μm), recurrent, or myopic holes, pose significant surgical challenges. Their pathogenesis involves vitreomacular traction, with classifications (Gass, IVTS, CLOSE) guiding management. Despite standard pars plana vitrectomy (PPV) with internal limiting membrane (ILM) peeling achieving >90% closure in typical cases, success rates decline in complex scenarios. This review evaluates evolving surgical techniques for challenging FTMHs, focusing on anatomical and functional outcomes of novel ILM flap modifications, adjuvant therapies, and alternative approaches. A synthesis of clinical studies, meta-analyses, and case series was conducted. Key techniques analyzed include inverted ILM flaps, perfluorocarbon liquid (PFCL)-assisted stabilization, viscoat adhesion, retracting-door flaps, and advanced methods like autologous retinal transplantation (ART), human amniotic membrane (hAM) grafts and Plasma-rich growth factor (PRGF). The inverted ILM flap technique demonstrated superior closure rates (95.6% vs. 78.6% with conventional peeling) for large holes. PFCL and viscoat further enhanced stability, achieving 100% closure in high myopia. For holes >800 μm , hAM grafts and ART showed 100% and 90.5% closure, respectively, with ART improving vision by four lines. (PRGF) membranes also facilitated closure in refractory cases. Advanced ILM flap techniques and adjunctive strategies significantly improve outcomes for challenging FTMHs. Tailored approaches based on hole size, etiology, and ocular anatomy are critical. Further research is warranted to optimize protocols for giant holes (>1000 μm) and validate emerging therapies like PRGF.



This work is licensed under a Creative Commons Attribution Non-Commercial 4.0 International License.

1. INTRODUCTION

Full thickness macular hole (FTMH), a full-thickness anatomical defect of the fovea disrupting all neuroretinal layers, was initially characterized by [1]. The pathogenesis of MH is primarily attributed to residual vitreous cortical traction subsequent to posterior vitreous detachment. This vitreoretinal interface force exerts dynamic stresses upon the macular region, resulting in intraretinal edema and the progressive

separation and retraction of inner retinal layers, thereby facilitating hole formation and expansion [2- 4]. While idiopathic MHs constitute the predominant etiology, accounting for approximately 85% of cases, secondary causes include blunt ocular trauma, high myopia, macular schisis, macular telangiectasia type 2, neovascular age-related macular degeneration complicated by anti-VEGF therapy, and iatrogenic surgical trauma [5].

The demographic profile of MH patients is characterized by a predilection for women exceeding 65 years of age, with a demonstrated association with myopia [6]. Epidemiological studies indicate a prevalence of approximately 3.3 per 1000 individuals in the general population, with bilateral involvement reported in 10-15% of cases [7].

Classification of Idiopathic Macular Holes

Currently, three primary classification systems are utilized to categorize FTMH. The initial classification, described by Gass, is predicated upon clinical observations detailing the progressive evolution of the MH [1].

Subsequently, The International Vitreomacular Traction Study (IVTS) Group has proposed a more contemporary classification scheme. This latter system incorporates the presence and characteristics of vitreomacular adhesion (VMA) and vitreomacular traction (VMT), in concert with the specific morphological attributes of the MH, thereby providing a more comprehensive framework for assessment [5].

The CLOSE study group has introduced a novel surgical classification system specifically designed for large FTMHs, while also identifying optical coherence tomography (OCT) biomarkers for potential application in clinical practice and future investigations. This classification has demonstrated that large (400–550 μm) and extra-large (550–800 μm) FTMHs can be effectively managed utilizing internal limiting membrane (ILM) peeling and ILM flap techniques, respectively. However, further research is imperative to evaluate the optimal surgical approaches for the treatment of larger FTMHs, designated as XX-large and giant, utilizing the CLOSE classification. These studies are necessary to determine the most appropriate surgical technique based on hole size and specific morphological characteristics [8].

Stage of Full-Thickness MH	Gass Classification	IVTS Classification	CLOSE classification	
			Hole Size (μm)	Classification
0	Previous MH with no foveal architecture changes and VMA in the fellow eye	VMA	< 250	Small
1	Impending macular hole with foveal architecture change	VMT without MH	> 250 - \leq 400	Medium
2	MH with preexisting VMA	Small-sized or medium-sized MH with VMT	> 400 - \leq 650	Large
3	\geq 400 μm MH without	Medium-sized or Large-	> 650 - \leq 800	X-large

	VMA	sized MH with VMT		
4	MH with complete vitreous separation	Any sized MH without VMT	> 800 - ≤ 1000	XX-large
			> 1000	Giant

Challenging FTMHs include recurrent ones, persistent or refractory, macular holes in eyes with pathological myopia and large macular holes with an inner diameter of more than 650 μm [9- 11].

Surgical techniques used in treatment of challenging macular holes

The combination of pars plana vitrectomy (PPV), posterior hyaloid elevation, ILM peeling, and fluid-air exchange with subsequent gas tamponade continues to be the gold-standard surgical strategy for treating FTMHs [12]. This approach demonstrates high efficacy, achieving anatomical closure rates exceeding 90% and best-corrected visual acuity (BCVA) improvements of two or more lines in over 70% of cases [8], [9]. Nevertheless, approximately 10% of FTMHs do not achieve successful closure, even with optimal surgical adherence to this established protocol [13]. Suboptimal outcomes are frequently observed in cases involving myopic eyes or macular holes with a minimum linear diameter (MLD) exceeding 500 μm [14], [15].

In 2010, [16] introduced the inverted ILM flap technique, a novel modification to conventional macular hole surgery. Their initial study demonstrated anatomic closure in 98% of eyes with (FTMHs) $\geq 400 \mu\text{m}$ in minimum linear diameter (MLD) treated with the inverted flap, compared to 88% closure in eyes undergoing standard ILM peeling alone. Subsequent studies corroborated these findings. For example, [13] reported significantly higher anatomic success rates in a retrospective analysis of 620 eyes: 95.6% closure with the inverted flap versus 78.6% with conventional ILM peeling for MHs $\geq 400 \mu\text{m}$. Notably, in myopic eyes (axial length $\geq 26 \text{ mm}$), closure rates improved from 38.9% with standard peeling to 88.4% with the inverted flap.

Further validation came from [17], who observed 94% anatomic closure in 68 eyes with large myopic FTMHs treated with the inverted flap, versus 61% with complete ILM peeling. Their analysis also revealed that the inverted flap technique conferred a 22-fold higher probability of anatomic success across all FTMH sizes.

A meta-analysis encompassing over 1,400 eyes further solidified these outcomes, highlighting the inverted flap's statistically significant advantage in closure rates for large FTMHs, myopic eyes, and cases complicated by retinal detachment [18].

Although the inverted ILM flap technique has demonstrated considerable success, the treatment of large and atypical (FTMHs) continues to pose significant challenges, particularly in cases involving high myopia or holes with MLD $\geq 500 \mu\text{m}$.

For instance, the Manchester Large Macular Hole Study revealed that FTMHs with a diameter $\geq 630 \mu\text{m}$ exhibited markedly reduced closure rates, prompting the proposal of this revised MLD threshold to better categorize "large" MHs based on their surgical prognosis with conventional ILM peeling. The study emphasized that these diminished closure rates necessitate supplementary approaches, such as ILM flap techniques [14].

Similarly, findings from the BEAVRS Macular Hole Study Group highlighted a progressive decline in

anatomic closure success for MHs exceeding MLD ≥ 500 μm , underscoring the persistent demand for innovative surgical strategies to address these complex cases [15].

Novel ILM Flap techniques

Numerous innovative adaptations of the ILM flap technique have been developed to address complex MH presentations, demonstrating enhanced efficacy in anatomically demanding cases.

Shin et al. pioneered the utilization of perfluorocarbon liquid (PFCL) to stabilize inverted ILM flaps during fluid-air exchange, effectively mitigating intraoperative displacement risks. Their investigation revealed that PFCL-assisted inverted ILM flaps achieved complete anatomic closure in all cases of MHs with a mean minimum linear diameter (MLD) of 590.8 μm . Furthermore, the study documented a statistically significant improvement in anatomic success rates compared to conventional ILM peeling at the 6-month postoperative interval [19].

In a complementary approach, Song et al. established a refined surgical protocol involving the intracameral administration of a viscoelastic agent (viscoat) to optimize flap adherence. The technique entails precise viscoat injection adjacent to (FTMH), intraoperative indocyanine green (ICG) staining for enhanced ILM visualization, meticulous creation of a superiorly hinged inverted ILM flap, and subsequent viscoat application over the flap prior to fluid-air exchange [20].

When applied to a cohort of highly myopic eyes (mean axial length: 29.83 mm) with MHs averaging 597.6 μm MLD, this method achieved universal anatomic closure (100%) and conferred measurable improvements in (BCVA) in 66.7% of cases, underscoring its clinical relevance in managing structurally intricate pathologies.

To manage the anatomical challenges of myopic macular holes (MHs), Finn and Mahmoud introduced the *retracting-door ILM flap technique*. This approach involves creating an ILM flap starting at the nasal edge of the hole, extending it over the fovea while preserving a temporal attachment, and repositioning it to cover the MH. The technique minimizes surgical manipulation, reduces tractional forces, and allows the taut ILM to relax naturally [21].

Marlow et al. later adapted this method for cases where MHs coexist with epiretinal membranes (ERMs). Their modification combined ERM removal with ILM flap creation, enabling effective treatment of both pathologies while maintaining retinal structure [22].

The *flower-petal inverted ILM flap* is another successful variant, utilizing multiple ILM leaflets layered sequentially to create a scaffold over the macular hole [23]. In a study of 103 eyes with large FTMHs ; mean MLD: 712 μm), Joshi et al. employed this technique with (PFCL), achieving anatomic closure in 92.2% of cases [24].

This approach is particularly advantageous in highly myopic eyes with posterior staphyloma, where ILM fragmentation often complicates surgical repair.

Over the past decade, numerous ILM flap techniques have demonstrated efficacy. Each method presents unique benefits and limitations, necessitating careful selection based on the FTMH's configuration, ocular anatomy, and the surgeon's expertise.

Managing Complex Cases

More invasive surgical techniques are typically reserved for patients with very large (MHs), where the success rate of (ILM) flap procedures declines proportionally as the (MLD) exceeds 750 μm . In such cases, recent studies highlight the efficacy of alternative approaches, including human amniotic membrane graft (hAM), macular hydrodissection, and autologous retinal transplantation (ART), which have demonstrated superior outcomes compared to conventional methods [8], [25].

The CLOSE Study Group conducted a comparative analysis of adjuvant surgical interventions for (FTMHs) exceeding 800 μm in (MLD). Anatomic closure rates varied across techniques: (hAM) grafts achieved a 100% success rate, (ART) demonstrated 90.5% closure, and macular hydrodissection yielded 83.3% closure. Notably, ART was uniquely associated with significant functional gains, delivering a mean improvement of four lines in best-corrected visual acuity (BCVA) for FTMHs $\geq 1,000$ μm [8]. Emerging evidence suggests that a combined hAM-ART approach represents a promising therapeutic strategy for large myopic FTMHs complicated by outer retinal atrophy [26].

Refractory (FTMHs) pose a considerable challenge due to their size, frequent association with high myopia or chronicity, and limited (ILM). For refractory macular holes measuring ≤ 750 μm with inadequate ILM after prior repair, viable surgical options include ILM free flaps, autologous retinal transplantation (ART), human amniotic membrane (hAM) grafts, and macular hydrodissection.

Surgical management of refractory macular holes requires careful consideration of technique limitations. Internal limiting membrane (ILM) free flaps, while an option, carry risks of intraoperative displacement and non-anatomical ILM fragment insertion, potentially limiting glial stimulation and neurosensory retinal restoration. (ART) and (hAM) grafts offer structural tissue plugs but are typically reserved for larger defects. Conversely, for eyes with adequate residual ILM post-peeling, the wide-base ILM flap transposition technique provides a physiologically aligned approach. By repositioning a robust, hinged ILM flap over the defect, this method has demonstrated both anatomical success and improved visual outcomes, offering a potentially superior alternative to free flaps [10].

This surgical technique involves harvesting a wide-base (ILM) flap from an area distal to prior peeling, which is then inverted and draped over the macular hole (MH) to achieve anatomic coverage. In cases with prior ILM flap intervention, the existing flap can be repositioned under (PFCL) to stabilize its placement over the defect. A slow, controlled fluid-air exchange is subsequently performed, followed by long-acting gas tamponade to minimize displacement risks. For refractory macular holes ≥ 750 μm , autologous retinal transplantation (ART) or combined human amniotic membrane-ART (hAM-ART) is preferred to address the absence of neurosensory tissue and ensure structural restoration.

[27] state that autologous retinal transplantation in patients with primary large chronic macular holes resulted in improved integrity of outer retinal layers, with corresponding improvement in visual acuity and function on microperimetry, without any significant complications.

[28] suggest that inducing macular detachment during vitrectomy with subretinal injection of balanced salt solution may be a viable alternative surgical technique for persistent and recurrent macular holes, especially in cases with flat macular holes. They state that this technique should be considered in any case where a 360-degree ILM peel with a 2-disc diameter radius was previously performed, as the retina may become intrinsically stiff after ILM peeling.

[29] successfully used a plasma-rich growth factors (PRGF) membrane as adjunctive therapy in the surgical repair of a recurrent large myopic macular hole (MH) in a 71-year-old patient. After initial closure via (PPV) with (ILM) peeling, the MH recurred (700 μm diameter) with persistent poor visual acuity. A second surgery involved extended ILM peeling, placement of an autologous PRGF membrane into the MH, and fluid-gas exchange. Postoperatively, the MH closed completely within two months, with restored foveal anatomy and improved visual acuity (0.1 logMAR). No adverse effects or recurrences were observed over six months. The PRGF membrane, rich in growth factors like EGF and PDGF, likely facilitated tissue regeneration and acted as a scaffold for glial cell proliferation, enhancing anatomic and functional recovery.

The PRGF membrane demonstrates promise as an effective adjunct in managing recurrent large myopic macular holes, particularly in cases refractory to conventional ILM peeling. Its mechanical support and bioactive properties promote tissue healing without adverse events, offering a viable option for complex retinal surgeries. This case highlights the potential of PRGF technology to improve outcomes in challenging MH scenarios, warranting further clinical studies to validate its broader applicability [29].

Conclusion

Challenging (FTMHs), including large (>650 μm), recurrent, and myopic variants, demand advanced surgical strategies beyond conventional (PPV) with (ILM) peeling. The inverted ILM flap technique has revolutionized management, achieving closure rates of 95.6% for large holes compared to 78.6% with standard peeling, particularly in myopic eyes where PFCL stabilization and viscoat adhesion further enhance success (100% closure). For giant FTMHs (>1000 μm), human amniotic membrane (hAM) grafts and autologous retinal transplantation (ART) demonstrate exceptional efficacy, with hAM achieving 100% anatomical closure and ART delivering a mean visual gain of four lines, underscoring their role in restoring structural and functional integrity. Innovations like the retracting-door flap and (PRGF) membranes address refractory cases by minimizing traction and leveraging bioactive scaffolds, respectively.

Tailored surgical approaches, guided by hole size, etiology (e.g., high myopia, posterior staphyloma), and residual ILM availability, are paramount. While current advancements significantly improve outcomes, standardization of techniques, long-term visual and anatomical outcomes, and comparative trials for emerging adjuncts like PRGF require further investigation. Collaborative efforts to refine the CLOSE classification's prognostic utility and optimize protocols for ultra-large holes (>1000 μm) will be critical in advancing the precision and accessibility of macular hole surgery globally.

References

- [1] Johnson, R.N. and J.D.M.J.O. Gass, Idiopathic macular holes: observations, stages of formation, and implications for surgical intervention. 1988. 95(7): p. 917-924.
- [2] Azzolini, C.J.J.o.O., Macular hole: from diagnosis to therapy. 2020. 2020: p. 1473763.
- [3] Ezra, E.J.B.J.o.O., Idiopathic full thickness macular hole: natural history and pathogenesis. 2001. 85(1): p. 102-109.
- [4] Tornambe, P.E.J.R., Macular hole genesis: the hydration theory. 2003. 23(3): p. 421-424.
- [5] Duker, J.S., et al., The International Vitreomacular Traction Study Group classification of vitreomacular adhesion, traction, and macular hole. 2013. 120(12): p. 2611-2619.

- [6] Ali, F.S., et al., Incidence of and risk factors for developing idiopathic macular hole among a diverse group of patients throughout the United States. 2017. 135(4): p. 299-305.
- [7] Rahmani, B., et al., The cause-specific prevalence of visual impairment in an urban population: the Baltimore Eye Survey. 1996. 103(11): p. 1721-1726.
- [8] Rezende, F.A., et al., Surgical classification for large macular hole: based on different surgical techniques results: the CLOSE study group. 2023. 9(1): p. 4.
- [9] Mahmoud, T.H. and J.T.J.O.R. Thompson, The treatment of difficult macular holes. 2021. 5(4): p. 315-316.
- [10] Tabandeh, H., et al., Superior wide-base internal limiting membrane flap transposition for macular holes: flap status and outcomes. 2021. 5(4): p. 317-323.
- [11] Valldeperas, X. and D.J.O. Wong, Is it worth reoperating on macular holes? 2008. 115(1): p. 158-163.
- [12] Kelly, N.E. and R.T.J.A.o.o. Wendel, Vitreous surgery for idiopathic macular holes: results of a pilot study. 1991. 109(5): p. 654-659.
- [13] Rizzo, S., et al., Internal limiting membrane peeling versus inverted flap technique for treatment of full-thickness macular holes: a comparative study in a large series of patients. 2018. 38: p. S73-S78.
- [14] Ch'ng, S.W., et al., The Manchester large macular hole study: is it time to reclassify large macular holes? 2018. 195: p. 36-42.
- [15] Steel, D., et al., Factors affecting anatomical and visual outcome after macular hole surgery: findings from a large prospective UK cohort. 2021. 35(1): p. 316-325.
- [16] Michalewska, Z., et al., Inverted internal limiting membrane flap technique for large macular holes. 2010. 117(10): p. 2018-2025.
- [17] Mete, M., et al., Inverted internal limiting membrane flap technique versus complete internal limiting membrane removal in myopic macular hole surgery: a comparative study. 2017. 37(10): p. 1923-1930.
- [18] Marques, R.E., et al., Complete ILM peeling versus inverted flap technique for macular hole surgery: a meta-analysis. 2020. 51(3): p. 187-A2.
- [19] Shin, M.K., et al., Perfluoro-n-Octane-assisted single-layered inverted internal limiting membrane flap technique for macular hole surgery. 2014. 34(9): p. 1905-1910.
- [20] Song, Z., et al., Viscoat assisted inverted internal limiting membrane flap technique for large macular holes associated with high myopia. 2016. 2016(1): p. 8283062.
- [21] Finn, A.P. and T.H.J.R. Mahmoud, Internal limiting membrane retracting door for myopic macular

holes. 2019. 39: p. S92-S94.

[22] Marlow, E.D., et al., Combined epiretinal and internal limiting membrane retracting door flaps for large macular holes associated with epiretinal membranes. 2022. 260(8): p. 2433-2436.

[23] Aurora, A., et al., Cabbage leaf inverted flap ILM peeling for macular hole: a novel technique. 2017. 48(10): p. 830-832.

[24] Joshi, S., et al., Surgical outcomes of petalloid multilayered inverted internal limiting membrane flaps in extra-large macular holes. 2024. 72(Suppl 1): p. S153-S157.

[25] Moysidis, S.N., et al., Autologous retinal transplantation for primary and refractory macular holes and macular hole retinal detachments: the global consortium. 2021. 128(5): p. 672-685.

[26] Tauqeer, Z., et al., Combined Amniotic Membrane Graft and Autologous Retinal Transplant for Repair of Refractory Chronic Myopic Macular Holes. 2022: p. 10.1097.

[27] Tanaka, S., et al., Autologous retinal transplantation as a primary treatment for large chronic macular holes. 2020. 40(10): p. 1938-1945.

[28] Szigiato, A.-A., et al., Induction of macular detachment for the treatment of persistent or recurrent idiopathic macular holes. 2016. 36(9): p. 1694-1698.

[29] Sánchez-Ávila, R.M., et al., Treatment of recurrent myopic macular hole using membrane of plasma rich in growth factors. 2019: p. 229-233.